

profile[™]
COSTAL CARTILAGE ALLOGRAFT

CLINICAL COMPENDIUM

[Key Figures & Tables](#)

[Clinical Study Summaries](#)

TABLE OF CONTENTS



Article	page
Introduction	2
Hanna, S, Mattos, D, Shaishav, D, Reish, R. Outcomes of the Use of Fresh Frozen Costal Cartilage in Rhinoplasty	4
Wan, R, Weissman, J, Williams, T, Ullrich, P, Joshi, C, Huffman, K, Galiano, R. Prospective Clinical Trial Evaluating the Outcomes Associated with the Use of Fresh Frozen Allograft Cartilage in Rhinoplasty	5
Wan, R, Weissman, J, Ullrich, P, Joshi, C, Williams, T, Galiano, R. The Utilization of Fresh Frozen Cartilage in Asian Rhinoplasty: A New Approach	7
Milkovich, J, Ahmad, J. A Canadian Experience with Off-the-Shelf, Aseptically Processed, Costal Cartilage Segment Allografts in Complex Rhinoplasty	8
Chen, K, Schultz, B, Mattos, D, Reish, R. Optimizing the Use of Autografts, Allografts, and Alloplastic Materials in Rhinoplasty	10
Rohrich, R, Abraham, J, Alleyne, B, Bellamy, J, Mohan, R. Fresh Frozen Rib Cartilage Grafts in Revision Rhinoplasty: A 9-Year Experience	14
Rogal, J, Glasgold, A, Glasgold, RA. Safety and Efficacy of Non- and Minimally Irradiated Homologous Costal Cartilage in Primary and Revision Rhinoplasty	16
Rohrich, R, Shanmugakrishnan, R, Mohan, R. Rhinoplasty Refinements: Revision Rhinoplasty Using Fresh Frozen Costal Cartilage Allograft	18
Mohan, R, Krishnan, R, Rohrich, R. Role of Fresh Frozen Cartilage in Revision Rhinoplasty	20
Key Figures and Tables	22

INTRODUCTION

Rhinoplasty Procedures Trending Up

Since the launch of costal cartilage sheets in 2016, the Profile® portfolio of costal cartilage grafts has grown to include surgeon users at more than 800 hospitals and practices throughout the US as well as Canada, Equador, Puerto Rico, Republic of Korea, Switzerland, Turkey and UAE.

This growth is in keeping with the surge in demand for rhinoplasty. In 2020, Rhinoplasty was the most requested cosmetic surgery in the US, with more than 352,000 procedures performed¹. This is believed to be a result of more people working from home during the pandemic, which has caused a “zoom boom;” people seeing themselves on camera during virtual meetings and finding things they want to change about their appearance. Working from home also allows for the downtime needed to recover from this and other major surgical procedures.

Growing Use of Allograft Costal Cartilage

As rhinoplasty procedures grow, so does the use of allograft in not only revision but primary rhinos as well. Autologous costal cartilage is still the gold standard, but allograft usage is much more widely accepted and often preferred. Profile® has been a major catalyst in this shift, as Profile performs better than other allografts have historically. This is attributed to the fact that Profile is the **only non-terminally irradiated costal cartilage allograft** available on the market today.

The Profile Difference

According to Dr. Rod Rohrich, “the terminal radiation process for sterilization likely contributes to decreased viability and contextual structural integrity of the graft, which is avoided in fresh frozen rib cartilage grafts (**Fresh Frozen Rib Cartilage Grafts in Revision Rhinoplasty: A 9-Year Experience**. Page 60. 2022)” In all of his Profile publications, Dr. Rohrich highlights the processing differences between “fresh frozen” costal cartilage (Profile) and terminally sterilized allografts offered by other tissue banks.

In addition to being the only allograft for rhinoplasty that is not terminally sterilized, Profile also has the **widest selection of sizes (14)** and is the **only allograft that is available in sheets with a precut thickness of 2mm**. This provides further convenience to the surgeon and reduces OR time and risk of comorbidities associated with autograft harvest, not the least of which is pain, “often the main memory patients have from autologous rib harvest” (Rohrich’s 9-year Study, Page 61).

Profile also provides off-the-shelf grafting material of known quality, important when performing rhinoplasty on older patients whose own costal cartilage may be compromised due to ossification or calcification.

Compendium Overview

In this compendium you will find summaries for each of the studies currently published on the use of Profile costal cartilage in rhinoplasty. Each summary includes links to the actual clinical paper on the Profile product webpage of the MTF website. The compendium also contains buttons that allow the reader to easily toggle between sections, including the **“Key Figures and Tables”** section.

Two of the papers in the compendium are primarily didactic (Rohrich R. “Rhinoplasty Refinements.” and Reish, R. “Optimizing ... **Materials in Rhinoplasty.**”) explaining the authors preferred techniques and grafting materials. Dr. Reish’s study provides a thorough overview including advantages and disadvantages and preferred areas of placement for all presently available options for rhinoplasty grafting materials, including autograft, allograft and alloplasts, and states Profile “should be considered any time septal cartilage may not be available...”

Dr. Rohrich's "[Rhinoplasty Refinements...paper](#)" published in 2020 details his procedure for correcting a crooked nose with retracted columella in a 28-year-old patient with a history of previous rhinoplasty, using Profile to create extended spreader grafts and a columellar strut. The paper includes three [videos](#) for visualization of his techniques and practices.

The other seven studies showcase the clinical **safety and efficacy of Profile in a total of 659 patients over more than nine years.**

This collection of published studies provides assurance that Profile is a safe, reliable, cost-effective rhinoplasty grafting material for your practice.

Please contact your MTF Biologics Surgical Consultant or click [here](#) for more information on Profile.

¹Plastic Surgery Statistics Report. American Society of Plastic Surgeons. @ASPS 2021.

Title: Outcomes of the Use of Fresh Frozen Costal Cartilage in Rhinoplasty

Author: Hanna, S, Mattos, D, Datta, S, Reish, R.

Source: *Plast Reconstr Surg* 2023 Oct 9. doi: 10.1097/PRS.00000000000011125. Online ahead of print.

[Full Publication](#)

STUDY OBJECTIVE

Determine the long-term stability of Fresh Frozen Costal Cartilage (FFCC) by assessing infection rate, warping, resorption, and associated surgical revision rates.

METHODS

Retrospective study analyzing rates of infection, warping and resorption of Fresh Frozen Costal Cartilage (FFCC) grafts in 282 patients undergoing rhinoplasty in the senior author's practice between March 2018 and December 2021. The inclusion criteria were cases with a minimum of 12 months of follow-up. The study included both revision rhinoplasty patients as well as primary rhinoplasty patients, secondary to trauma, intranasal medication use, cocaine use, previous septoplasty, or generally insufficient cartilage.

RESULTS

The study includes 282 patients who underwent either primary rhinoplasty, secondary to trauma, intranasal medication use, cocaine use, previous septoplasty, or generally insufficient cartilage, (14.2%) or revision rhinoplasty (85.8%) with the use of FFCC. Most participants were female (90.4%), with mean age of 35.8 years old (range: 15 to 68 years old). The mean follow-up period was 20.3 months, with a minimum of 12 months follow-up.

Six patients (2.1%) demonstrated signs of infection which required treatment with empiric antibiotics, with all cases resolving without need for further antibiotic or operative management. None of the patients in our review had clinical signs of warping, resorption, or displacement of the FFCC grafts. There were six patients (2.1%) who required a return to the operating room for further revision rhinoplasty.

CONCLUSION

FFCC is a safe, convenient, and patient-centered option for graft tissue in rhinoplasty. Acute infection, warping, and resorption rates were found to be no greater than rhinoplasty complication rates when autologous or homologous tissue are used.

Title: Prospective Clinical Trial Evaluating the Outcomes Associated with the Use of Fresh Frozen Allograft Cartilage in Rhinoplasty

Author: Wan, R, Weissman, J, Williams, T, Joshi, C, Huffman, K, Galiano, R.

Source: *PRS Global Open*. October 2023. DOI: 10.1097/GOX.00000000000005315KTakeaways

[Full Publication](#)

STUDY OBJECTIVE

Compare the outcomes of fresh frozen costal cartilage allograft (Profile®) and traditional autologous costal cartilage in cosmetic and reconstructive rhinoplasty procedures.

METHODS

Prospective, single-center, nonrandomized, open-label clinical trial to evaluate warping, resorption, and cartilage displacement in 50 patients by measuring the differences of standardized values (deviation angle, nasofrontal angle, total facial convexity, nasofacial angle, and nasolabial angle) obtained at 6-months and 12-months postoperative follow-up on standard two-dimensional photographs (Δ = measurement 6 measurement 12).

Subjective assessment was measured by the FACE-Q assessment completed by the patients preoperatively, and at 1 week, 6 weeks, 12 weeks, 6 months, and 12 months postoperatively. Each assessment is a set of four to 17 statements, including satisfaction with overall facial appearance, satisfaction with nose, satisfaction with nostrils, social function, psychological well-being, and so on, for which the patients rated their agreement on a scale of 1–4.

Postoperative adverse effects, including clinically evident resorption, warping, graft displacement, scarring, and infection, were also recorded at every assessment visit.

RESULTS

Fifty patients underwent rhinoplasty using fresh frozen costal cartilage allograft (25 patients) or autologous costal cartilage (25 patients) between March 2017 and October 2020. Nine patients underwent Asian rhinoplasty, 12 patients had reconstruction after Mohs and 9 patients had revision rhinoplasty. The average patient age was 43.9 ± 16.6 years and the mean follow-up period was 14.8 months.

In the control group, the changes (Δ) in the deviation angle, nasofrontal angle, total facial convexity and nasolabial angle were greater than in the CCA group ($P < 0.05$). See Figure 3 for additional details.

Patient Satisfaction

In the CCA group, the mean score of satisfaction with nose improved at 6 months and 1 year postoperatively ($P < 0.05$). The mean score of satisfaction with nostrils and overall facial appearance was greater for those patients who utilized allograft cartilage ($P < 0.05$) vs autologous cartilage.

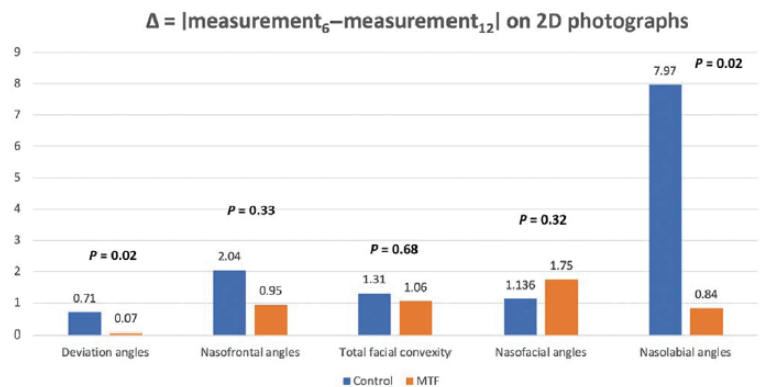


Fig. 3. The change of the measurements ($\Delta = |\text{measurement}_6 - \text{measurement}_{12}|$) of deviation angle, nasofrontal angle, total facial convexity, and nasolabial angle on standard 2D photographs at 6- and 12-months postoperative visits.

Postoperative Complications

Total postoperative complications in the control group were 10 vs 6 with costal cartilage allograft (CCA), with a higher rate of infection (1 vs 0), warping (3 vs 2) and scarring (4 vs 2) in the control group. Rates of resorption were the same between the two groups. See Table 4. Postoperative Complications.

Table 4: Postoperative Complications

Complications	Control	CCA
Infection	1	0
Resorption	2	2
Warping	3	2
Pneumothorax	0	NA
Scarring	4	2
Total	10	6

CCA, costal cartilage allograft; NA, not applicable

CONCLUSION

Non-terminally sterilized fresh frozen CCA is a useful, safe, reliable, and economical source of cartilage in reconstructive and cosmetic rhinoplasty in comparison to autologous costal cartilage. It is aseptic, readily available, previously tailored, and free of donor site complications. The objective assessment in the study demonstrated long-standing structural support in the CCA group with no significant changes in the values of deviation angle, nasofrontal angle, total facial convexity, nasofacial angle, and the nasolabial angle at 6-months and 12-months follow-up. Most patients in the CCA group benefited from having only one surgical site, reduced time of harvesting the cartilage grafts, and decreased operating room cost.

Of note, despite the cost of shipment and storage of the fresh frozen cartilage the full price of the surgery was still lower than using the autologous costal cartilage. In addition to the reduction in overall surgical fees, using CCA vs autologous cartilage, the observed reduction in narcotic medications also represents a significant benefit.

Title: The Utilization of Fresh Frozen Cartilage in Asian Rhinoplasty: A New Approach

Author: Wan, R, Weissman, J, Ullrich, P, Joshi, C, Williams, T, Galiano, R.

Source: *PRS Global Open*. April 2023. <https://doi.org/10.1097/GOX.0000000000004903>

Full Publication

STUDY OBJECTIVE

Prospective study to evaluate and report the use of fresh frozen allograft cartilage from the Musculoskeletal Transplant Foundation (Edison, N.J.) for rhinoplasty in five Asian patients.

METHODS

Five Asian rhinoplasties using fresh frozen allograft costal cartilage were performed by the senior author between May 2018 and January 2020. Patients were followed up for an average of 14.2 ± 3.35 months.

Before and after photographs were taken in a standard photograph room. Anthropometric measurements on standard two-dimensional photographs were collected. Four measurements were taken, and the changes in the values between two follow-up visits were documented ($\Delta = |\text{measurement}_{\text{visit1}} - \text{measurement}_{\text{visit2}}|$) to assess resorption and warping.

FACE-Q scales⁶ were used to assess patient-reported outcomes. The FACE-Q Satisfaction with Nose and the FACE-Q Satisfaction with Nostrils include 10 and five items, respectively. A higher score indicated a higher degree of satisfaction.

Postoperative complications were also recorded.

RESULTS

There were no major adverse events or complications among any patients. No resorption or warping was recorded at 1-year follow-up. The objective measurements had a mean of 0.93 degrees, ranging from 0.01 degrees to 3.63 degrees. At the time of the 1-year follow-up, mean FACE-Q Satisfaction with Nose, and Satisfaction with Nostrils scores improved from a preoperative score of 35.2 ± 10.06 to 60 ± 15.48 ($P = 0.0002$), and from a preoperative score of 42.6 ± 20.31 to 59.8 ± 38.21 ($P = 0.12$), respectively.

CONCLUSION

Fresh frozen costal cartilage is an excellent option for Asian rhinoplasty. Compared with current standards, it has the advantages of a more abundant supply, no donor site morbidity, shorter operative time, and lower surgical costs. Our case series also proves that it is safe and yields satisfactory surgical outcomes. Further investigation involving a greater number of patients and longer follow-up time is needed.

Title: A Canadian Experience with Off-the-Shelf, Aseptically Processed, Costal Cartilage Segment Allografts in Complex Rhinoplasty

Author: Milkovich, J, Ahmad, J.

Source: *Aesthetic Surgery Journal Open Forum* 2022, 1-7.
www.asjopenforum.com

Paper Presentation. The Aesthetic Meeting, Apr 2023

Full Publication

STUDY OBJECTIVE

Evaluate the safety and efficacy of aseptically processed, non-terminally sterilized costal cartilage segment allografts (CCSAs) in complex primary and secondary rhinoplasty procedures performed in Canada.

METHODS

Retrospective review of twenty-one patients who received non-terminally sterilized costal cartilage segment allografts between June 2019 and April 2022 during primary or secondary rhinoplasty. Eleven of the procedures were primary rhinoplasties and ten were secondary. The mean operative time was 185 minutes. Follow up time ranged from 2.0-37.8 months with a mean of 15 months.

Grafts carved included columellar strut (9, 42.8%), septal extension (13, 61.9%), Alar contour (16, 66.1%) Dorsal onlay (2, 9.5%), Extended spreader (10, 47.6%), Splinting (7, 33.3%), Infratip shield (2, 9.5%), Lateral crural strut (5, 23.8%) and Diced cartilage (1, 4.8%).

CCSAs were carved with cuts made in the anterior-posterior orientation as opposed to cranial-caudal orientation. Figure 1 shows CCSA carved in the correct (on the right) vs incorrect (on the left) orientation.

Grafts were also carved from the central segment of the CCSA (Figure 2) vs peripheral carving which has a higher tendency toward warping.



Figure 1. It is important to carve the segments in the correct orientation using more central sheets which have less potential to warp. Peripheral sheets have much more tendency toward warping. With reference to the native anatomic position, the costal cartilage segment should be carved into sheets with cuts made in the anterior-posterior orientation as opposed to the cranial-caudal orientation. The piece of cartilage on the left was carved from the periphery of the rib in the cranial-caudal orientation, while the piece of cartilage on the right was carved from the center of the rib in the anterior-posterior orientation.

RESULTS

Nineteen patients (90.5%) reported being very satisfied with their aesthetic results with the remaining two patients being satisfied. There was no evidence of aesthetic deformity secondary to graft warping. One patient (4.8%) experienced some resorption when the CCSA was modified to be used as diced cartilage wrapped in autologous temporal fascia for dorsal augmentation. Two patients (9.5%) underwent revision surgery for further aesthetic refinement not attributed to failure of the CCSA.

At revision the previously placed CCSAs were observed to be intact in both patients.

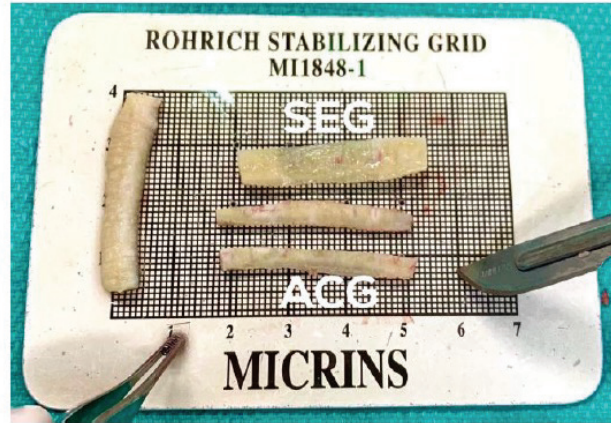

Figure 2. Grafts carved from the central segment of a fresh frozen, nonterminally sterilized, costal cartilage. ACG, alar contour graft; SEG, septal extension graft.

CONCLUSION

Overall, fresh frozen, aseptically processed and non-terminally sterilized CCSAs meet the criteria for an ideal grafting material in primary and secondary rhinoplasty when inadequate autologous cartilage is available from the nose, avoiding donor -site morbidity.

Title: Optimizing the Use of Autografts, Allografts, and Alloplastic Materials in Rhinoplasty

Author: Chen, K, Schultz, B, Mattos, D, Reish, R.

Source: *Plast. Reconstr. Surg.* 150:675e, 2022

[Full Publication](#)

STUDY OBJECTIVE

Review of current and most common options available for graft source and implant material and the techniques in graft/implant choice and placement in both primary and revision rhinoplasties.

METHODS

The pros, cons and optimal areas for placement for the following rhinoplasty grafting materials are reviewed:

Autograft: Septal cartilage, Auricular/Conchal cartilage, Costal Cartilage, Bone Grafts

Allografts: Irradiated Costal Cartilage, Nonirradiated costal cartilage (Profile)

Alloplasts: Silicone, High-density Polyethylene, Polytetrafluoroethylene, Gore-Tex, Polydioxanone Foil

RESULTS

AUTOGRAFT

Septal cartilage is the work horse for rhinoplasty. Easy to access and harvest with minimal donor site morbidity, it provides a straight, large source of cartilage. While it can be made into spreader grafts, septal extension grafts, columellar strut, batten grafts and alar rim contour grafts, it tends to be too stiff for tip grafts (palpable in thin-skinned patients).

Auricular/Conchal cartilage is a convenient cartilage source when septal cartilage is not available. It is softer and more pliable than septal cartilage, making it ideal for tip grafts such as onlay grafts and lateral crural strut grafts but less desirable for structural grafts.

Costal Cartilage offers an abundant source of structurally sound cartilage, especially when septal cartilage is not available. It is often a first choice of cartilage in Asian patients who may have short or insufficient septal cartilage. It carries low rates of warping (3%) and resorption (.22%) but high morbidity associated with harvest, including the risk of pneumothorax, as well as chest scarring (hypertrophic in patients of Asian and African descent).

Bone Grafts are a reliable source of rigid autograft that can produce reliable results. Calvarial bone is often the site of choice given its proximity to the head and neck and well-hidden donor site scar. Given its rigidity, the edges of this graft may be palpable and it may be more predisposed to resorption compared to autograft cartilage grafts. Fascia may be used as an adjunct graft to camouflage the edges of bone and other grafts when needed.

ALLOGRAFT

Costal Cartilage: Irradiated vs Nonirradiated

Irradiated costal cartilage was introduced as an option to provide costal cartilage without the donor-site morbidities (pain, scarring, pneumothorax) associated with autologous cartilage harvest. These grafts have proven to be safe but, compared to autologous costal cartilage, have demonstrated a much higher rate of (31% resorption rate vs 3% with autologous costal cartilage) and histological differences in chondrocyte viability and collagen fiber content, causing them to fall out of favor for use in rhinoplasty.

However, in recent years, fresh frozen costal cartilage allograft (Profile) was introduced by MTF Biologics. It is processed without irradiation and is cleaned using an antibiotic soak. It's available as a sheet which decreases the need to carve the graft. See Videos [1](#), [2](#) and [3](#) for the author's technique for using extended spreader grafts, columellar struts and alar contour grafts, respectively.

Nuances to working with the graft:

Allow graft to fully thaw before using. If warping occurs after thawing the graft, select the straightest part of the graft for use or use oppositional suture techniques (*Figure 2*) to control and counteract the warping. See Video [4](#) to learn Dr. Reish's technique for thawing Profile prior to use. Cartilage from older donors appears yellow and heterogeneous and is stiffer and less prone to warping. Cartilage from younger donors appears white and homogenous. A sheet graft can be divided and used for the following grafts: Bilateral alar rim grafts, spreader grafts and a columellar strut (*Figure 3*).

Although there is a paucity of long-term data on the use of fresh frozen costal cartilage, Dr. Rohrich's study ([Role of Fresh Frozen Cartilage in Revision Rhinoplasty.2019](#)) shows good results in 50 patients with little resorption.

Fresh frozen costal cartilage allograft use decreases operative time associated with harvesting a second source of autologous cartilage and should be considered any time septal cartilage may be not available and the need for grafts is anticipated.

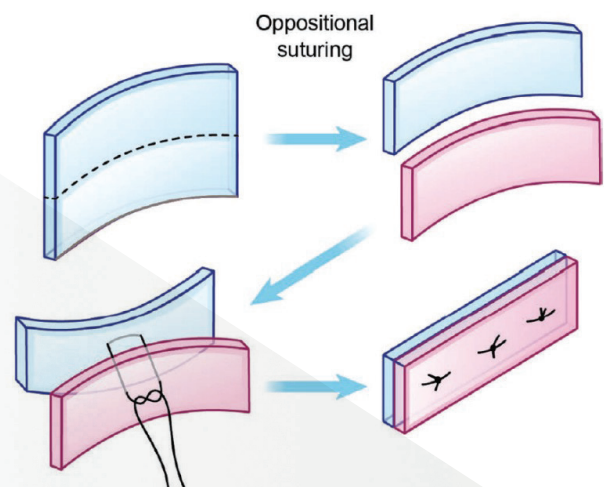


Fig. 2. This figure demonstrates the technique of oppositional suturing.

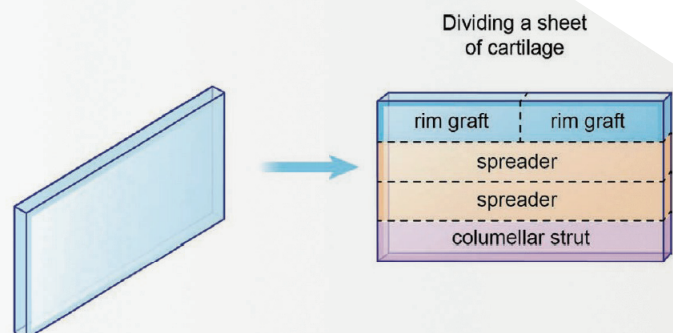


Fig. 3. This figure demonstrates the typical method of dividing a sheet of cartilage for use in the nose.

ALLOPLASTIC MATERIALS

Silicone is frequently used for nasal augmentation, especially in Asian populations. It provides an easy-to-use material with low foreign body reaction that is easily carved and customized to the patient. However, revision procedures to remove silicone implants are increasingly common because the solid construct without pores does not allow for vascular or soft-tissue ingrowth, causing chronic inflammation and formation of a thick fibrous capsule which can lead to bacterial colonization and capsular contracture and deformity. Capsular contracture occurs at a rate of 34.8% and results in tip deviation, short nose deformity, implant demarcation, color change and functional problems up to twenty years post implantation. Revision rhinoplasty is often necessary to remove the capsule and implant and correct the shortened nose. Extrusion of silicone implants is another issue and occurs as high as 10% for dorsal nasal implants and 50% for columellar struts. Silicone nasal implants may also become displaced due to insufficient implant fixation, implant placement in the suprapariosteal plane and over-augmentation with inappropriately large implants. These overly large implants may cause increased pressure on the columella and nasal tips, leading to higher rates of soft tissue ischemia, necrosis and eventual perforation and extrusion requiring removal. Of all alloplasts, silicone has the highest rate of complication requiring removal. Prolonged implantation of silicone implants induces calcification with up to 50% of implants showing evidence of calcification after 9 years and visible deformities secondary to calcification were found in implants up to 15 years after implantation.

High-Density Polyethylene (Medpor®)

Medpor is a porous product made of high-density polyethylene developed in the 1970s for facial augmentation. It is highly flexible and relatively noncompressible, allowing it to be easily carved. And because of its excellent biocompatibility profile, Medpor may be applied directly onto the facial bones as an onlay implant using sutures or screws. It is often used for correction of a severe saddle nose deformity, overresected nose and other nasal deformities. However, it is often stiff and palpable and may be visible with an abnormal appearance and feel if not used in conjunction with a camouflage graft. The large pore size (200 µm) of Medpor allows for vascular ingrowth and enhanced implant fixation but shedding of particles in mobile or stress-bearing areas may lead to chronic inflammation and subsequent tissue fibrosis. Thinning over the overlying skin envelope, contour irregularities and full-thickness button holing upon explantation may occur. Cases of Medpor extrusion in the nasal dorsum and tip have been reported. Turned up or short nose and tip stiffness are the most common reasons for revision in patients receiving Medpor implants.

Polytetrafluoroethylene is a hydrophobic carbon/fluorine polymer with pores up to 30 µm allowing for tissue ingrowth. Introduced in 1971, Gore-Tex, an expanded polytetrafluoroethylene, was approved for soft tissue augmentation. The three Gore-Tex patch sizes are pliable and easily cut, carved, and beveled with a scalpel or scissors. This material is best suited for treating an overresected dorsum but owing to its minimal rigidity and tensile strength, should be avoided when structural support is needed, such as in reconstruction of the nasal valve or septum or when tip-columellar subunits is performed.

Polydioxanone Foil is a biodegradable, crystalline colorless polymer commonly used as a suture material but also available as a thin foil sheet. It's absorbable, and stiff but thin, making it suitable for correction of septal deviation and reinforcement of other grafts, such as columellar struts and alar batten grafts. It is well tolerated with minimal infection and extrusion.

CONCLUSION

A movement away from reductive rhinoplasty has many plastic surgeons looking to use grafts for structural support. While septal cartilage remains the ideal source for most needed grafts, alternative graft materials such as nonirradiated cadaveric costal cartilage (Profile) are attractive options to avoid donor site harvest and morbidity. Clinical experience and understanding of this and other available materials is needed. Refer to Table 1 from the paper for a direct comparison between all materials reviewed.

Table 1 provides a comparison of complication rates, including resorption, infection and extrusion, as well as cost, among the materials discussed in the paper.

Table 1. Complication Rates of Homologous Grafts and Allogenic Implants*

Graft	Resorption	Infection	Extrusion	Relative Cost
Fresh frozen cadaveric cartilage	Very low	Very low	Very low	+++
Irradiated cartilage	Moderate to high	Low	Low	++++
Freeze-dried acellular dermis	Moderate to high	Very low	Very low	++++
Silicone	Very low	Low to moderate	Moderate to high	+
High-density polyethylene	Very low	Low	Moderate	+++
Polytetrafluoroethylene	Very low	Low to moderate	Low	++
Hydroxyapatite	Variable	Variable	Variable	++
Polydioxanone foil	High	Very low	Very low	+

*Table 1 is a simplification of the complication rates, which may vary depending on implant location, implantation technique, and application.

Very low, <1%; low, 1–5%; moderate, 5-15%; high, >15%.

Title: Fresh Frozen Rib Cartilage Grafts in Revision Rhinoplasty: A 9-Year Experience

Author: Rohrich, R, Abraham, J, Alleyne, B, Bellamy, J, Mohan, R.

Source: *Plast. Reconstr. Surg.* 150:58, 2022.

[Full Publication](#)

STUDY OBJECTIVE

Retrospective review to assess rates of warping, resorption, displacement, and infection in 226 patients who underwent primary or revision rhinoplasty by Dr. Rod Rohrich between 2011 and 2020 using fresh frozen costal cartilage (Profile®).

METHODS

A retrospective review of medical charts for complications, including warping, resorption, displacement, infection and reoperation was performed for 226 patients who underwent open rhinoplasty with fresh frozen allograft cartilage produced by MTF Biologics. All procedures were performed by the senior author (Rohrich) at the Dallas Plastic Surgery Institute between 2011 and 2020. Location of grafts, number of prior rhinoplasties, patient age and length of follow up were also reviewed. Follow up ranged from 6 mos to 8 years with a mean follow-up period of 12.18 months.

Patient & Procedural Information:

- Female: 82%/Male: 18%
- Patient Age Range: 19-74 Mean Patient age: 40.59
- Avg # of previous rhinoplasty procedures: 54% had one prior rhinoplasty;4% had undergone four or more nose procedures
- Types of Grafts Used: (%)
 - Alar contour (49%)
 - Columellar strut 23%
 - Dorsal Onlay (12%)
 - Lateral Nasal Wall (4%)
 - Septal extension (40%)

RESULTS:

Overall infection rate was 2.7% (n=6). Mild nasal tip erythema was noted in nine patients (4.0%), all cases of which were self-limiting and resolved within two -three weeks. Six patients experienced warping (three with dorsal only grafts ,two with alar contour grafts, one with septal extension graft). Four of the six patients underwent reoperation for replacement or repositioning of the grafts. None of the patients experienced displacement or extrusion. These results were compared with historical data on autologous and irradiated grafts (Table 3).

Table 3. Comparison of Autologous, Irradiated Homologous, Tutoplast Homologous, and Fresh Frozen Nonirradiated Allografts in Revision Rhinoplasty

Complication	Autologous (%)*†	Irradiated Homologous (%)†	Tutoplast Homologous (%)†	Fresh Frozen (%) (n = 226)
Warping	3.1-6	5	4	2.7
Infection	0.6-2	3	0	2.7
Resorption	0.2-1	4	11	N/A
Pneumothorax	0 (0-0.3)	N/A	N/A	N/A
Revision surgery	5-14.1	7	3	2.2

N/A, not applicable.

*Wee JH, Park M-H, Oh S, Jin H-R. Complications associated with autologous rib cartilage use in rhinoplasty: A meta-analysis. *JAMA Facial Plast Surg.* 2015;17:49–55.

†Vila PM, Jeanpierre LM, Rizzi CJ, Yaeger LH, Chi JJ. Comparison of autologous vs homologous costal cartilage grafts in dorsal augmentation

rhinoplasty: A systematic review and meta-analysis. *JAMA Otolaryngol Head Neck Surg.* 2020;146:347–354.

Autologous cartilage and fresh frozen cartilage (Profile) appear to have similarly low rates of resorption, in stark contrast to irradiated homologous cartilage. The terminal radiation process likely contributes to decreased viability and contextual structural integrity of the grafts.

The risk for postoperative infection with fresh frozen rib cartilage is similar to both autologous and irradiated grafts and adequately managed with antibiotic therapy. Only one patient required reoperation which occurred six months after the explanation with no additional complications.

CONCLUSION

Revision rhinoplasty results are significantly enhanced with the creation of a stable framework using off the shelf, easily accessible, specifically tailored fresh frozen allograft rib grafts. This 9- year retrospective study demonstrates the safety and longevity of fresh frozen rib graft in comparison to autologous and irradiated homologous cartilage.

Title: Safety and Efficacy of Non- and Minimally Irradiated Homologous Costal Cartilage in Primary and Revision Rhinoplasty

Author: Rogal, J, Glasgold, A, Glasgold, RA.

Source: *Facial Plastic Surgery & Aesthetic Medicine.*
Volume 23, Number 1. 2021.

[Full Publication](#)

STUDY OBJECTIVE

Retrospectively evaluate the safety and efficacy of Non- or Minimally Irradiated Homologous Costal Cartilage (NIHCC) in primary and revision rhinoplasty

METHODS

- Retrospective review of 26 patients undergoing primary or revision rhinoplasty using NIHCC (Profile) between 2010 and 2014
 - Follow up range: 2-43.2 Mo Mean Follow up: 15.9 Mo
- All patients underwent open rhinoplasty
 - 7 patients underwent primary rhinoplasty
 - 19 patients underwent revision rhinoplasty
- A total of 100 NIHCC grafts were used
- Columellar strut grafts and extended shield grafts were used in all cases
- Surgery included some or none of the following additional grafts:
 - Septal extension grafts (4)
 - Spreader grafts (19)
 - Alar rim grafts (23)
 - Batten grafts (9)
 - Lateral crural strut grafts (6)
 - Dorsal Augmentation grafts (8)
- Patients were assessed for warping, infection, infective and non-infective resorption, graft mobility and extrusion.

RESULTS

- Non-infective resorption was noted in 2/77 grafts (2.6%)
- Infection occurred in 1/100 grafts (1%)
- Total complication rate was 3.6%
- No instances of warping, mobility or extrusion occurred

CONCLUSIONS

NIHCC is safe and effective for grafting in functional and cosmetic primary and secondary rhinoplasty.

Title: Rhinoplasty Refinements: Revision Rhinoplasty Using Fresh Frozen Costal Cartilage Allograft

Author: Rohrich, R, Shanmugakrishnan, R, Mohan, R.

Source: *PRS Journal*. Volume 145. Number 6. 2020.

[Full Publication](#)

STUDY OBJECTIVE

Retrospective case study of a single secondary rhinoplasty using fresh frozen allograft (Profile) to address a crooked nose and retracted columella.

Introduction: Dr. Rohrich defines a retracted columella and how to correct. He explains his preference for Profile vs. autologous rib cartilage (avoid donor-site morbidity) and irradiated costal cartilage allografts (higher incidence of resorption and infection resulting in poor patient satisfaction). He explains that he has used Profile in more than 50 patients with no cases of resorption and just one infection.

Table 1 compares key characteristics of septal, costal and conchal autograft cartilage as well as irradiated and fresh frozen allograft cartilage, including warping, donor site morbidity, ease of harvest, structural support and operative time with fresh frozen scoring as well as or better than autologous cartilages in all categories.

Table 1. Comparison of Grafts

Characteristic	Septal	Costal	Conchal	Irradiated	Fresh Frozen
Amount	++	+++	+	+++	+++
Donor-site morbidity	--	++	-	N/A	N/A
Warping	-	+	+	++	+
Ease of harvest	++	-	+	N/A	N/A
Structural support	+	++	-	+	+
Scarring	---	++	+	N/A	N/A
Operative time	-	++	+	-	-
Ease of carving	++	+	-	++	++

+, increased; -, decreased; N/A, not applicable.



PROCEDURE

Through a series of three videos, Dr. Rohrich explains his procedure for correcting a crooked nose with a retracted columella in a 28 year old woman. Profile was used to create extended spreader grafts and a columellar strut.

Video 1 Summary:

- Analysis of the nasal deformities
- Incision and approach in an open rhinoplasty
- Dorsal reduction procedure
- Exposure of the anterior septal angle

Video 2 Summary:

- Dr. Rohrich's percutaneous osteotomy technique
- Profile carving and fashioning into grafts to straighten the nose and correct the retracted columella
- Use of sutures to reduce flaring of the media crura

Video 3 Summary

- Tip refinement details, including suturing techniques and butterfly graft placement
- Use of alar contour grafts to support external nasal valve
- Columellar closure

CONCLUSION

Fresh frozen costal cartilage allograft is a promising cartilage graft material in secondary rhinoplasty which often requires costal cartilage grafts to rebuild cartilaginous framework

Title: Role of Fresh Frozen Cartilage in Revision Rhinoplasty

Author: Mohan, R, Krishnan, R, Rohrich, R.

Source: *Plast. Reconstr. Surg.*
144: 614, 2019

[Full Publication](#)

STUDY OBJECTIVE

Retrospective analysis of charts and photographs of 50 patients who underwent revision rhinoplasty between 2014 and 2017 using fresh frozen cartilage from the Musculoskeletal Transplant Foundation.

METHODS

A retrospective review of medical charts for complications, including infection, resorption and warping, was performed for 50 patients who underwent revision rhinoplasty with fresh frozen allograft cartilage produced by MTF Biologics. All procedures were performed by the senior author (Rohrich) at the Dallas Plastic Surgery Institute between 2014 and 2017.

Patient & Procedural Information:

- Female: 38 patients/Male: 12 patients
- Avg # of previous rhinoplasty procedures: 2.62
- Patient Age Range: 21-70. Mean Patient age: 40
- Operative time: 70-370 min. Avg: 159 min

Types of Grafts Used: No (%)

- Dorsal augmentation 15 (30)
- Alar contour 44 (88)
- Dorsal spreader 8 (16)
- Columellar strut 14 (28)
- Infratip 8 (16)
- Septal extension 3 (6)

In addition, to assess the aesthetic outcomes of each procedure, an objective evaluation of aesthetic results was performed by four blinded plastic surgeons. These surgeons reviewed preoperative and postoperative photographs of the patients in the study cohort. The outcomes were assessed using the Independent Rhinoplasty Outcome Score.

The following components were assessed: Symmetry, dorsal height, dorsal length, dorsal width, tip projection, tip rotation, tip width, and overall result; using a scoring system of 1-4.

1=no improvement. 2=moderate outcome. 3=good outcome. 4=excellent outcome.

Post-operative follow-up ranged between 1 and 18 months, with a mean follow up of 3.35 months.

RESULTS

One case of infection was reported in the 50 patients studied (2%). It was treated with minimal debridement and a short course of antibiotics. No cases of warping or resorption were reported.

Table 5 shows complication rates of Autograft costal cartilage and Irradiated and Fresh Frozen (Profile) allograft costal cartilage.

Table 5. Comparison of Autografts, Irradiated Allografts, and Fresh Frozen Nonirradiated Allografts for Use in Revision Rhinoplasty

Characteristic	Autologous (%)*	Irradiated (%)*	Fresh Frozen (%)
Warping	13	10	0
Infection	6	10	2
Resorption	3	30	0
Pneumothorax	2	N / A	N / A
Donor-site pain	0	N / A	N / A
Total no. of complications	27	45	2

N/A, not applicable.

*Wee JH, Park MH, Oh S, Jin HR. Complications associated with autologous rib cartilage use in rhinoplasty: A meta-analysis. *JAMA Facial Plast Surg.* 2015;17:49–55.

The average score for each component of the aesthetic outcomes by blinded surgeon was greater than 3 (good outcome).

CONCLUSION

Autologous costal cartilage is the predominant donor cartilage source in revision rhinoplasty. However, it is associated with postoperative pain and prolonged operating times, and carries the risk of pneumothorax, atelectasis, and the need for prolonged narcotic pain control. Allograft costal cartilage biologic mesh for reinforcement of complex repairs is a viable, safe option in complex cases delivering clinically acceptable short and mid-term results in challenging clinical situations.

Key Figures and Tables

Profile Clinical Compendium

Wan, R. Weissman, J, Williams, T, Ullrich, P.,Joshi, C, Huffman, K, Galiano, R.
Prospective Clinical Trial Evaluating the Outcomes Associated with the Use of Fresh Frozen Allograft Cartilage in Rhinoplasty

Figure 3 Table 4

Milkovich, J. Ahmad. J. *A Canadian Experience with Off-the-Shelf, Aseptically Processed, Costal Cartilage Segment Allografts in Complex Rhinoplasty*

Figure 1 Figure 2

Reish, R. *Optimizing the Use of Autografts, Allografts and Alloplastic Materials in Rhinoplasty.*

Figure 2 Figure 3 Table 1

Rohrich, R,Abraham, J, Alleyne, B, Bellamy, J. Mohan, R. *Fresh Frozen Rib Cartilage Grafts in Revision Rhinoplasty: A 9-Year Experience.*

Table 3

Rohrich, R. Shanmugakrishnan, R. Mohan, R. *Rhinoplasty Refinements: Revision Rhinoplasty Using Fresh Frozen Costal Cartilage Allograft.*

Table 1

Mohan, R, Krishnan, R, Rohrich, R. *Role of Fresh Frozen Cartilage in Revision Rhinoplasty.*

Table 5

Wan, R. Weissman, J, Williams, T, Ullrich, P., Joshi, C, Huffman, K, Galiano, R.
*Prospective Clinical Trial Evaluating the Outcomes Associated with the Use
of Fresh Frozen Allograft Cartilage in Rhinoplasty*

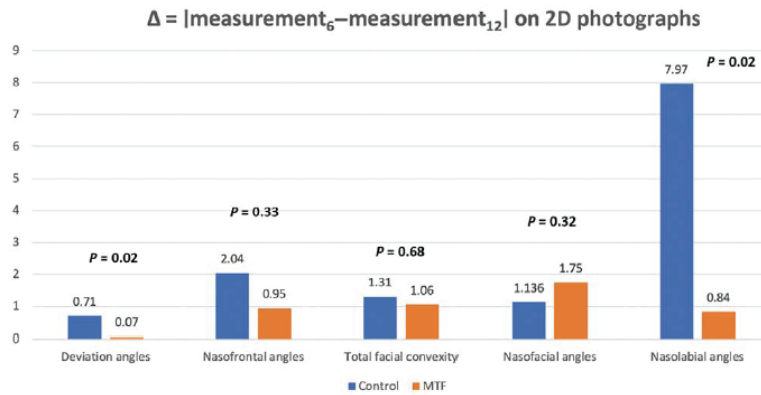


Fig. 3. The change of the measurements ($\Delta = |\text{measurement}_6 - \text{measurement}_{12}|$) of deviation angle, nasofrontal angle, total facial convexity, and nasolabial angle on standard 2D photographs at 6- and 12-months postoperative visits.

Table 4: Postoperative Complications

Complications	Control	CCA
Infection	1	0
Resorption	2	2
Warping	3	2
Pneumothorax	0	NA
Scarring	4	2
Total	10	6

CCA, costal cartilage allograft; NA, not applicable

PREVIOUS ◀

NEXT ▶

HOME 🏠

Milkovich, J, Ahmad, J. A Canadian Experience with Off-the-Shelf, Aseptically Processed, Costal Cartilage Segment Allografts in Complex Rhinoplasty.



Figure 1. It is important to carve the segments in the correct orientation using more central sheets which have less potential to warp. Peripheral sheets have much more tendency toward warping. With reference to the native anatomic position, the costal cartilage segment should be carved into sheets with cuts made in the anterior-posterior orientation as opposed to the cranial-caudal orientation. The piece of cartilage on the left was carved from the periphery of the rib in the cranial-caudal orientation, while the piece of cartilage on the right was carved from the center of the rib in the anterior-posterior orientation.

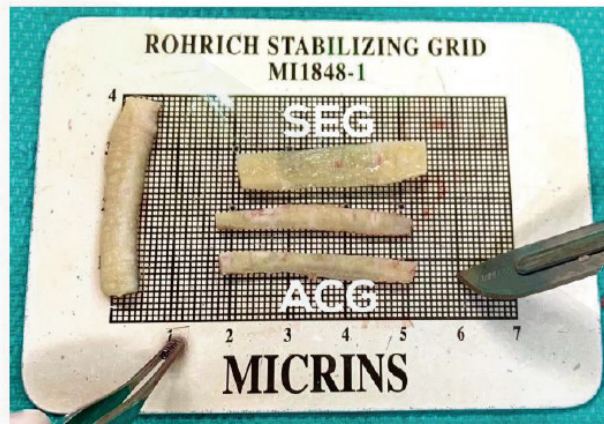


Figure 2. Grafts carved from the central segment of a fresh frozen, nonterminally sterilized, costal cartilage. ACG, alar contour graft; SEG, septal extension graft.

PREVIOUS ◀

NEXT ▶

HOME 🏠

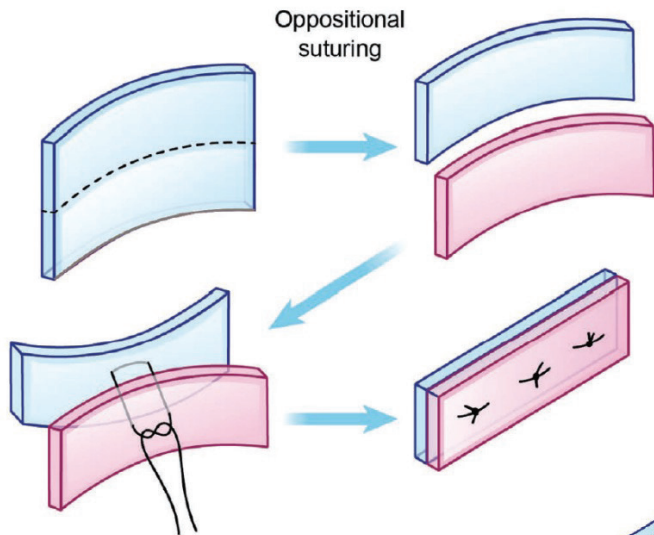


Fig. 2. This figure demonstrates the technique of oppositional suturing.

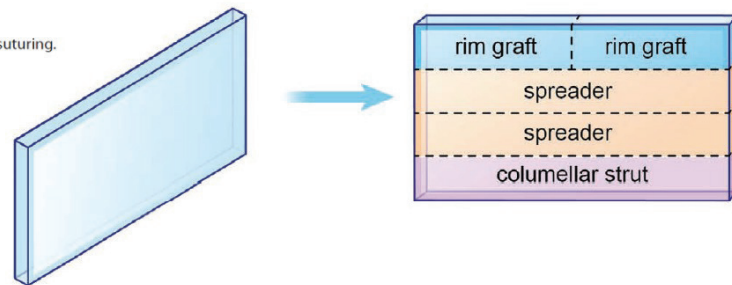


Fig. 3. This figure demonstrates the typical method of dividing a sheet of cartilage for use in the nose.

Reish, R. *Optimizing the Use of Autografts, Allografts and Alloplastic Materials in Rhinoplasty.*

Table 1. Complication Rates of Homologous Grafts and Allogenic Implants*

Graft	Resorption	Infection	Extrusion	Relative Cost
Fresh frozen cadaveric cartilage	Very low	Very low	Very low	+++
Irradiated cartilage	Moderate to high	Low	Low	++++
Freeze-dried acellular dermis	Moderate to high	Very low	Very low	++++
Silicone	Very low	Low to moderate	Moderate to high	+
High-density polyethylene	Very low	Low	Moderate	+++
Polytetrafluoroethylene	Very low	Low to moderate	Low	++
Hydroxyapatite	Variable	Variable	Variable	++
Polydioxanone foil	High	Very low	Very low	+

*Table 1 is a simplification of the complication rates, which may vary depending on implant location, implantation technique, and application.

Very low, <1%; low, 1–5%; moderate, 5-15%; high, >15%.

PREVIOUS

NEXT

HOME

Rohrich, R, Abraham, J, Alleyne, B, Bellamy, J. Mohan, R.
Fresh Frozen Rib Cartilage Grafts in Revision Rhinoplasty: A 9-Year Experience.

Table 3. Comparison of Autologous, Irradiated Homologous, Tutoplast Homologous, and Fresh Frozen Nonirradiated Allografts in Revision Rhinoplasty

Complication	Autologous (%) ^{*†}	Irradiated Homologous (%) [†]	Tutoplast Homologous (%) [†]	Fresh Frozen (%) (n = 226)
Warping	3.1-6	5	4	2.7
Infection	0.6-2	3	0	2.7
Resorption	0.2-1	4	11	N/A
Pneumothorax	0 (0-0.3)	N/A	N/A	N/A
Revision surgery	5-14.1	7	3	2.2

N/A, not applicable.

*Wee JH, Park M-H, Oh S, Jin H-R. Complications associated with autologous rib cartilage use in rhinoplasty: A meta-analysis. *JAMA Facial Plast Surg.* 2015;17:49–55.

†Vila PM, Jeanpierre LM, Rizzi CJ, Yaeger LH, Chi JJ. Comparison of autologous vs homologous costal cartilage grafts in dorsal augmentation rhinoplasty: A systematic review and meta-analysis. *JAMA Otolaryngol Head Neck Surg.* 2020;146:347–354.

PREVIOUS ◀

NEXT ▶

Table 1. Comparison of Grafts

Characteristic	Septal	Costal	Conchal	Irradiated	Fresh Frozen
Amount	++	+++	+	+++	+++
Donor-site morbidity	--	++	-	N/A	N/A
Warping	-	+	+	++	+
Ease of harvest	++	-	+	N/A	N/A
Structural support	+	++	-	+	+
Scarring	---	++	+	N/A	N/A
Operative time	-	++	+	-	-
Ease of carving	++	+	-	++	++

+, increased; -, decreased; N/A, not applicable.

PREVIOUS ◀

NEXT ▶

Mohan, R, Krishnan, R, Rohrich, R. *Role of Fresh Frozen Cartilage in Revision Rhinoplasty.*

Table 5. Comparison of Autografts, Irradiated Allografts, and Fresh Frozen Nonirradiated Allografts for Use in Revision Rhinoplasty

Characteristic	Autologous (%)*	Irradiated (%)*	Fresh Frozen (%)
Warping	13	10	0
Infection	6	10	2
Resorption	3	30	0
Pneumothorax	2	N / A	N / A
Donor-site pain	0	N / A	N / A
Total no. of complications	27	45	2

N/A, not applicable.

*Wee JH, Park MH, Oh S, Jin HR. Complications associated with autologous rib cartilage use in rhinoplasty: A meta-analysis. *JAMA Facial Plast Surg.* 2015;17:49–55.

PREVIOUS ◀

NEXT ▶

HOME 🏠

profile™

COSTAL CARTILAGE ALLOGRAFT



125 May Street, Edison, NJ, 08837 USA • 800-946-9008 • +1 (732) 661-0202 • mtfbiologics.org

Profile and MTF Biologics are registered trademarks of Musculoskeletal Transplant Foundation. ©2024

Mktg-1340, Rev 2.